

ANSC/FSTC 607
Physiology & Biochemistry of Muscle as a Food
Muscle Structure and Fiber types

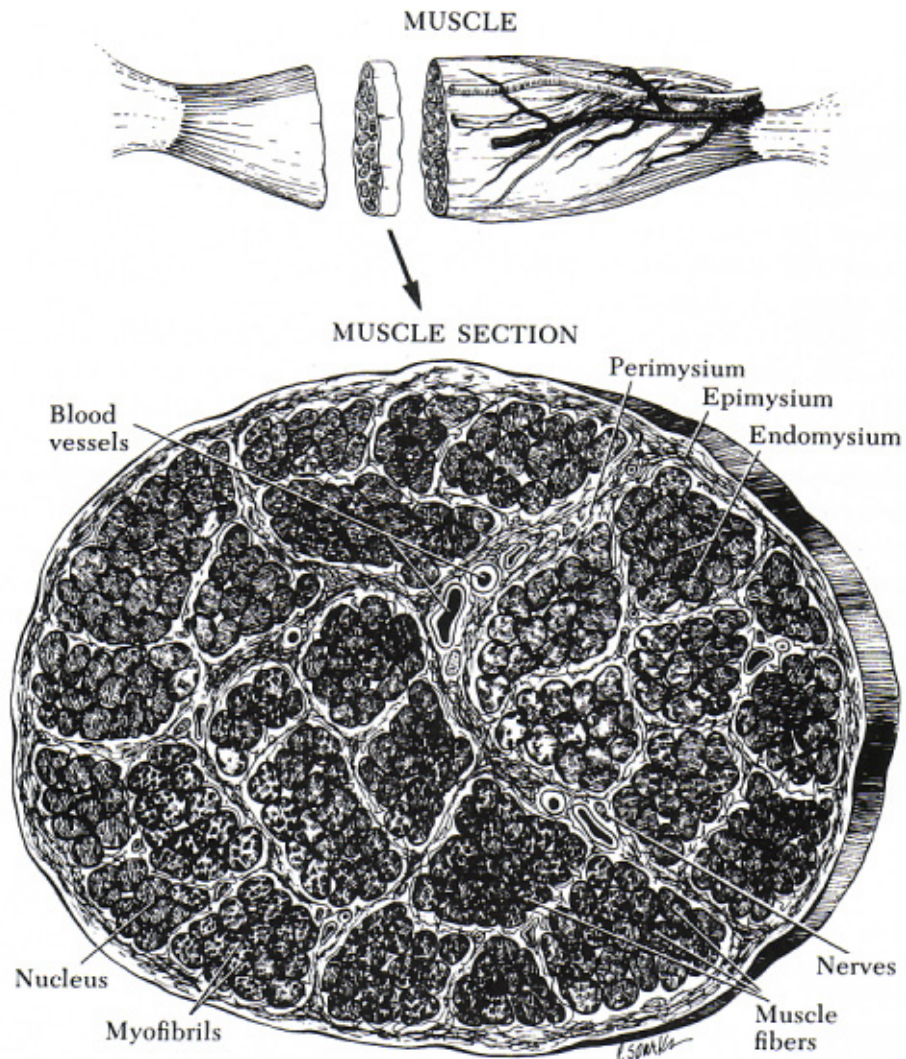
I. Levels of structure

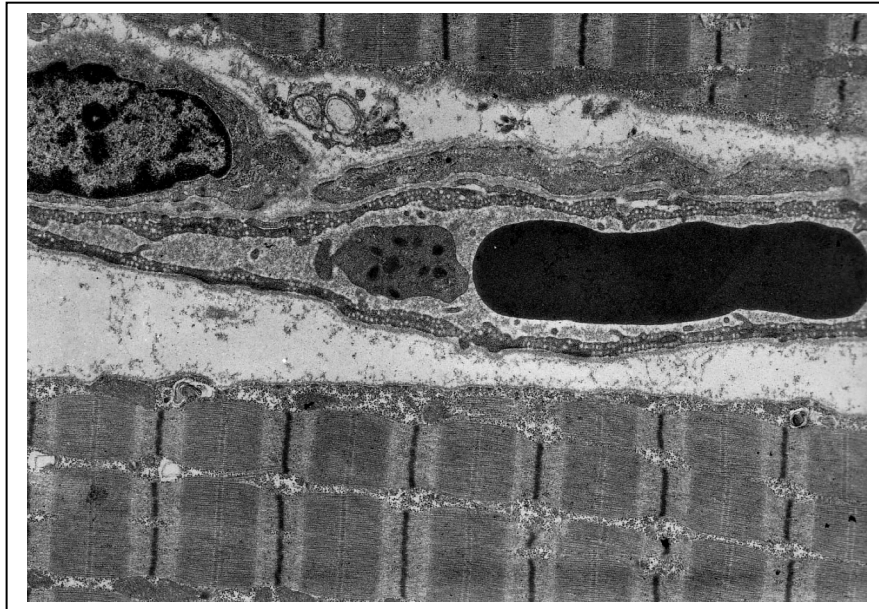
A. Muscle connective tissues

1. Epimysium around muscle body
2. Perimysium around muscle bundles
3. Endomysium around individual myofibers (muscle fibers)

B. Muscle bundle

1. Contain 10-20 myofibers
2. Encased by perimysium



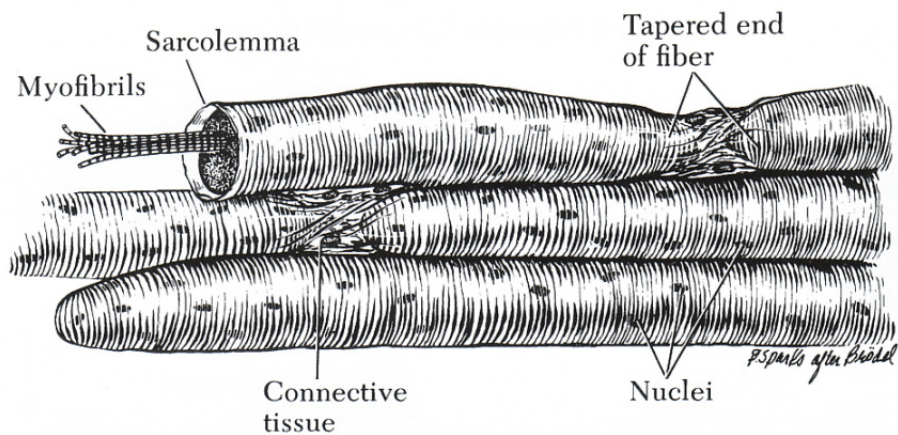


C. Capillaries and capillary endothelial cells

1. Between and surrounding individual myofibers
2. Separated from myofibers by *interstitial space*

D. Myofiber

1. Individual muscle cell
2. Multinucleated
3. Surrounded by a loose matrix of endomyseal connective tissue

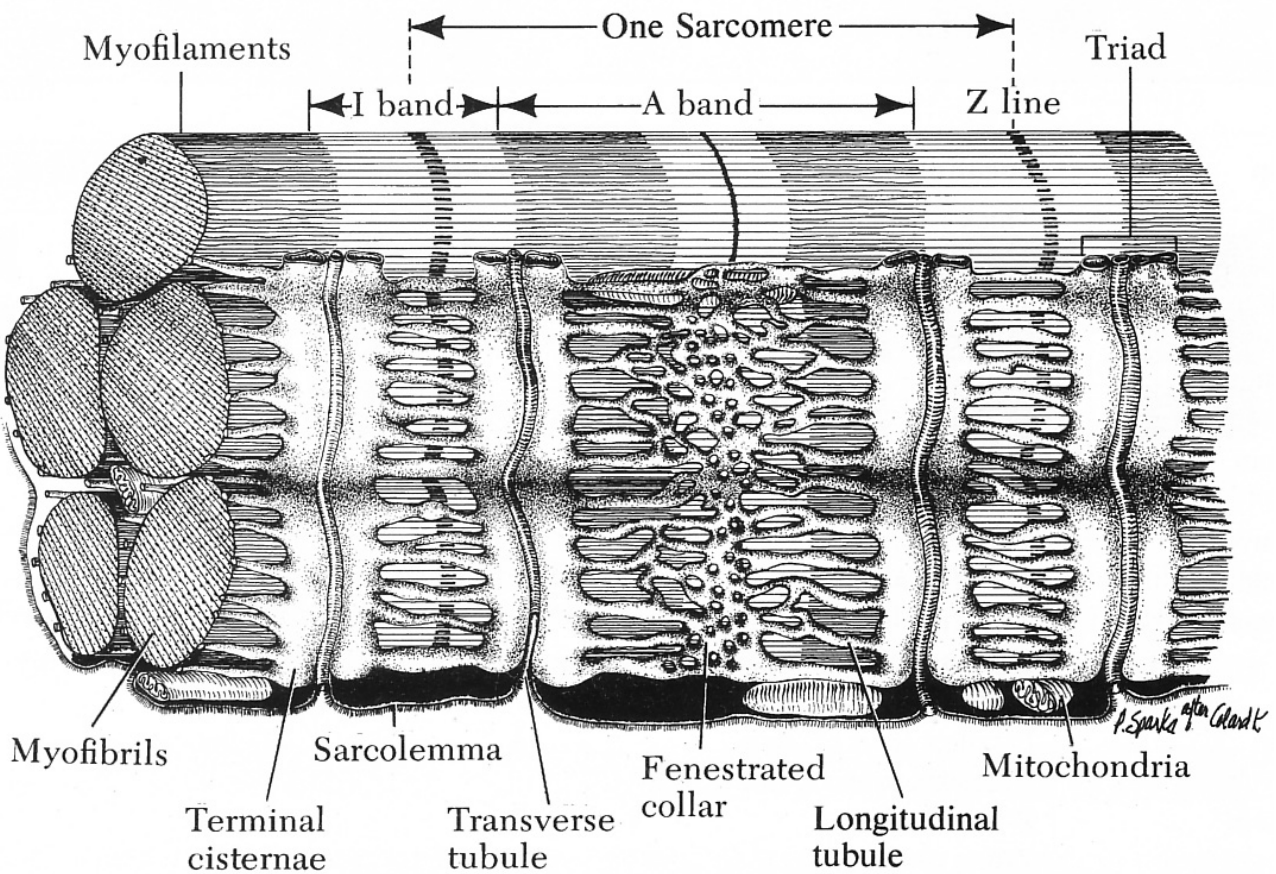


D. Myofibril

1. A band (constant width)
2. I band (variable width, depending on state of contraction)
3. Z disk (boundary of sarcomeres)
4. H zone (no overlapping thick and thin filaments; variable in width)
5. Pseudo-H zone (area of no myosin heads; constant width)

E. Sarcoplasmic reticulum

1. Surrounds every *myofibril* (not myofiber)
2. Composed terminal cisternae, longitudinal tubules, and fenestrated collars.
3. Site of calcium sequestering.

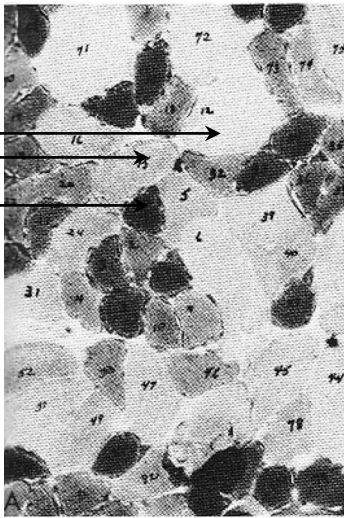

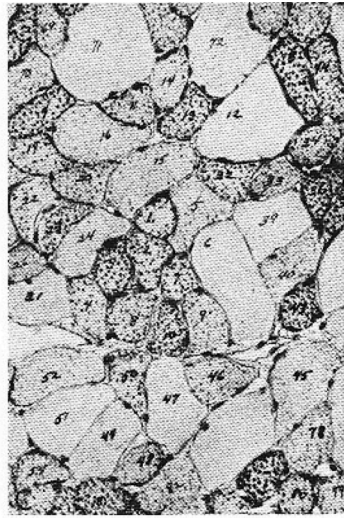


II. Muscle fiber types

A. Histochemical differences

Stain/reaction	Fiber Classification			
	α -Red	α -White	β -Red	β -White
	(IIA)	(IIB)	(IC)	(ID)
Alkali-stable ATPase	+++	++++	---	---
Acid-stable ATPase	---	---	++++	++++
NADH-tetrazolium reductase	++	---	++++	++++
Succinate dehydrogenase	++	---	++++	++
β -Hydroxybutyrate dehydrogenase	+	---	++++	++
Triacylglycerol esterase	+	---	++++	---
Mitochondrial ATPase	++	---	++++	---
Lipids	++	+	++++	+

White
Intermediate
Red

SERIAL CRYOSTAT SECTIONS OF DIAPHRAGM - ALBINO RAT

Classification of Fibers Based on Cytochemical Comparisons		
Type of Fiber	Percentage	Typical Examples in the Numbered Photographs Above
RED	60	1, 2, 3, 7, 8, 43
INTERMEDIATE	20	5, 15
WHITE	20	12, 71

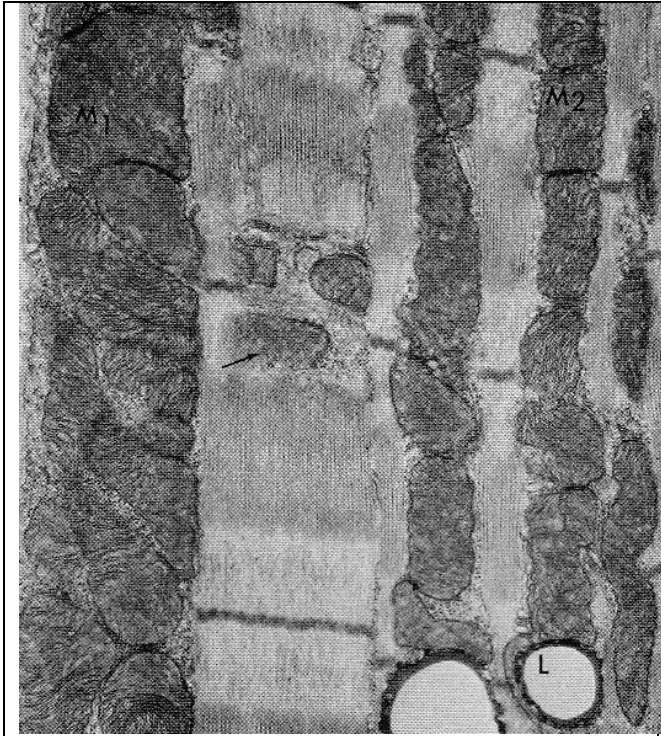
①

B. Biochemical differences

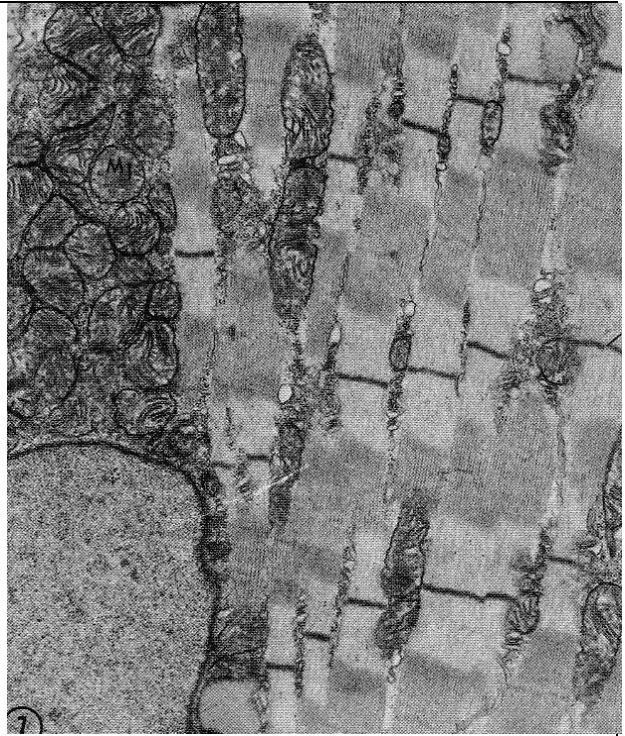
Enzyme System	Red Fibers	White Fibers
	<u>Activity ($\mu\text{mol}/\text{min}/\text{g}$ tissue)</u>	
Glycogen metabolism		
Phosphorylase	26	86
Glycogen synthetase	34	23
Glycolysis		
Hexokinase	93	12
6-Phosphofructokinase	729	1,710
G-3-P dehydrogenase	22	350
Pyruvate kinase	182	850
Tricarboxylic acid cycle		
Isocitrate dehydrogenase	41	5
Succinate dehydrogenase	59	22
Cytochrome oxidase	4	2
Fatty acid oxidation		
Acyl-CoA dehydrogenase	250	62

C. Ultrastructural differences


Characteristic	β -Red	α -Red	α -White
Mitochondria	Large, spherical subsarcolemmal mitochondria. Abundant intermyofibrillar mitochondria.	Fewer, smaller mitochondria	Very small, paired Z-line Mitochondria.
Z-lines (μm)	0.063 (thick, diffuse).	0.043	0.035 (thin, very sharp).
Sarcoplasmic reticulum	Narrow tubules.	Intermediate tubule structure.	Broad tubules (flattened sacs).



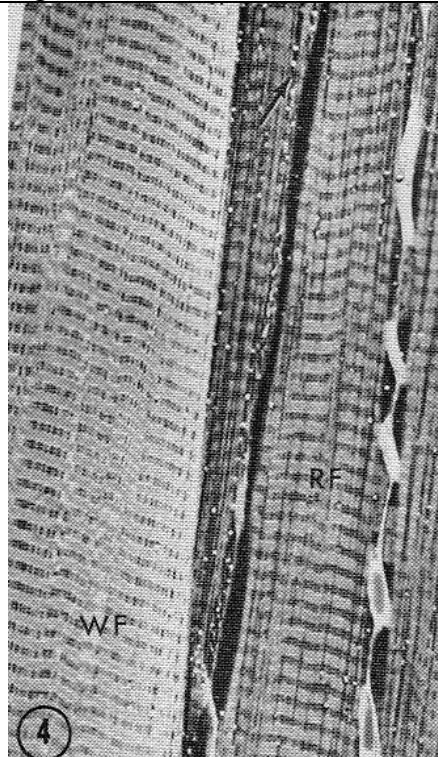
Diaphragm red fiber



Diaphragm intermediate fiber



Diaphragm white fiber



White and red diaphragm muscle fibers

D. Physiological/functional differences

Characteristic	β -Red	α -White
Twitch speed	Tonic (slow, with a long refractory period between twitches).	Phasic (very fast, with a short refractory period).
Size of motor unit (number of myofibers innervated by a single motoneuron)	Small (1 – 20 myofibers per motor unit). Designed for very fine movements (e.g., muscles within the eye) or long-endurance locomotion (e.g., soleus muscle).	Large (up to 200 myofibers per motor unit). Designed for rapid, massive movement (e.g., gastrocnemius muscle).
Motor end plate (site of attachment of the motoneuron to the myofiber)	Elliptical in shape, with few presynaptic vesicles. Few junctional folds.	Flat in shape, with abundant presynaptic vesicles. Highly involuted pre- and postsynaptic membranes.
Motoneurons (nerves innervating muscle fibers)	Small diameter (slow conducting), with no myelin sheaths.	Large diameter (fast conducting), with abundant myelin sheaths.